WHITE PAPER 2007
From Arthrex Vet Systems, Inc.

TIGHTROPE CCL FOR TREATMENT OF CRANIAL CRUCIATE DEFICIENCY IN DOGS:

Technique and results of a prospective comparison to TPLO using a validated outcome measures

James L. Cook, Jill K. Luther, Jodi Beetem, Cristi R. Cook
University of Missouri, Comparative Orthopaedic Laboratory

Cranial cruciate ligament (CCL) deficiency is a common and costly problem in dogs for which there are multiple treatment modalities. While numerous techniques have been investigated, none have proven optimal in terms of technical ease, associated costs, prevention of secondary pathology, complication rate or types, or long term outcomes. To the authors' knowledge, no technique for treatment of CCL deficiency has been shown superior to others in terms of functional outcome. We sought to investigate a stifle stabilization technique that had the potential to address perceived shortcomings of current techniques - specifically to be minimally invasive, technical feasible, address all aspects of instability, minimize secondary pathology, and consistently result in functional outcomes with a low complication rate in a cost effective manner. We prospectively compared the outcomes of our novel technique, the Tightrope CCL, to Tibial Plateau Leveling Osteotomy (TPLO).

The Tightrope CCL technique is based on the lateral retinacular imbrication suture (LRIS) principle. The theorized advantages of Tightrope over the LRIS include bone fixation at both tibial and femoral attachments, more accurate isometric placement, minimally invasive technique, and overall strength.

Fig. 1 - Tightrope CCL

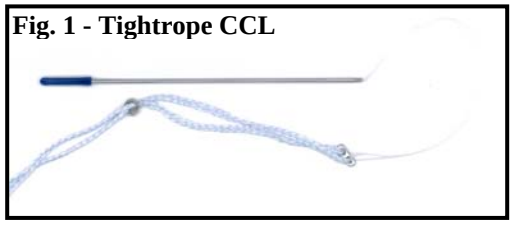

The Tightrope CCL device (Fig. 1) is placed after complete assessment and treatment of the joint via arthrotomy or arthroscopy. It is critical that intra-articular structures are completely evaluated and treated as indicated for successful surgical management of CCL deficiency. For placement of the Tightrope CCL, the lateral aspect of the stifle is exposed to the level of joint capsule from lateral fabella to tubercle of Gerdy (accomplished through approach for arthrotomy or separate incision after arthroscopy). A technique guide for the procedure is available from Arthrex Vet Systems, Inc. A pictorial summary of the technique is provided in Figure 2.

Fig. 2 - Tightrope Technique

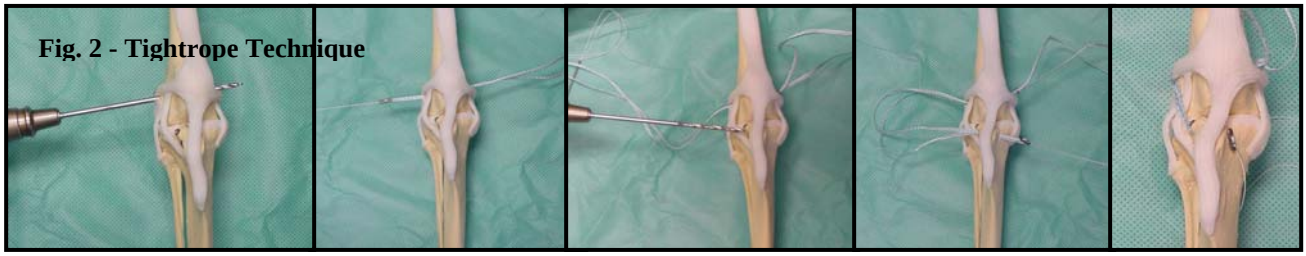

Outcomes for the first 24 consecutive patients receiving Tightrope CCL were assessed using the Texas A&M clinical questionnaire developed by Hudson, et al. (AJVR 2004) as the primary outcome measure (Fig. 3). Tightrope (TR) patients were prospectively compared to a cohort of patients undergoing TPLO (n=23) performed by the same surgeon in the same time period and with the same postoperative instructions. The study endpoint was 6 months postoperatively. Complications were recorded and subjective radiographic assessment was performed preoperatively and at endpoint. The Tightrope CCL technique was determined to be minimally invasive, relatively easy to perform, and cost effective in comparison to TPLO. The complication rates (12.5% TR vs 17.4% TPLO), including secondary meniscal tears (8.3% TR vs 8.4% TPLO), were similar between techniques. The data suggest that Tightrope can be successfully performed in medium, large, and giant breed dogs with CCL deficiency and result in 6-month outcomes which are as good as or better than TPLO in terms of function and radiographic progression of osteoarthritis. We do not recommend Tightrope in dogs which may have compromised connective tissue healing.

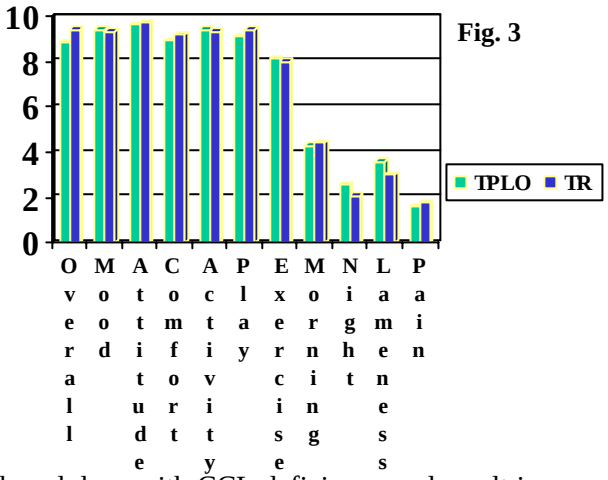

Fig. 3

Disclosure: JL Cook is a paid consultant for Arthrex. Tightrope CCL devices were provided by Arthrex for this study.